

ROOT CANAL MORPHOLOGY OF MANDIBULAR CANINE:- RETRO-SPECTIVE CROSS SECTIONAL CBCT STUDY.

Dr. Rohit Sharma¹, Dr. Sadaf Amreen², Dr. Atul Jain³, Dr. Madhurima Sharma⁴

1- Professor, 2- Post Graduate Student, 3- Professor And Head, 4- Professor, 1-3 – Department Of Conservative Dentistry And Endodontics, 4- Department Of Prosthodontics And Crown And Bridge, Teerthanker Mahaveer Dental College And Research Centre.

Abstract

The aim of the present study is to observe and evaluate root canal morphology of mandibular permanent canine in North Indian population using Cone Beam Computed Tomography (CBCT) images.

Materials and Method: 50 Cone Beam Computed Tomography scans of selected patient were taken on the basis of predetermined inclusion and exclusion criteria and evaluated that have images of mandibular permanent canine teeth, in north Indian males and females of 15-60 year groups age groups, from a data base CBCT scans taken from a CBCT scanning Centre located in Agra. Variation in root canal morphology of permanent mandibular canine teeth in male and female with different age group were noted and evaluated. The present study evaluate the root and root canal morphology of mandibular permanent Canine teeth.

Results: Statistical Analysis of collected data are carried out with Chi-sqaure test. In total of 98 mandibular canines evaluated ,Type I Cc found in 91 teeth(84%), Type II Cc found in 7 teeth(14%) and Type III Cc found in 1 teeth(2%).

Conclusions: On the basis of results obtained in this study it can be concluded that in north Indian population mostly type I canal configuration is found in permanent mandibular canine teeth that is around 91% with predominantly in male.

Introduction

The morphological variations in root canal system are found to be different in different teeth. For success of endodontic therapy it is very important to the do proper biomechanical preparation of the root canal system. For complete shaping, cleaning, and filling of root canal system is necessary which require a thorough understanding of the external and internal anatomy and its morphological variations.^[1,2] These variations play very crucial role in endodontic therapy as success or failure of endodontic treatment which depends on cleaning, shaping and debriding all root canals exists. Remnants of microorganisms and necrotic tissues inside the canals will definitely influence on the treatment outcomes.^[3] A The dependency of variation of root canal morphology on depend on different ethnic group of population as it linked with different races and it is also genetically dependant. So, a comprehensive knowledge of the root and internal anatomy of the teeth is fundamental for the proper cleaning of the root canal system and the consequent success of endodontic treatment^{1,2}

Different morphological variations of root canal system have been investigated and classified by several investigators and the most widely used is Vertucci's classification. Mandibular permanent canines typically present with single root and single root canal^[7,8] However, morphological variations have been existed and linked to various racial and genetic factors^[9,10] Several reports of anatomical variations of mandibular canine have been reported in the literature^[11,12] Single-rooted mandibular canine with two root canals has been reported to be approximately 15%.^[5,7,13] In addition, the incidence of mandibular canine having double roots and two root canals was reported to be up to

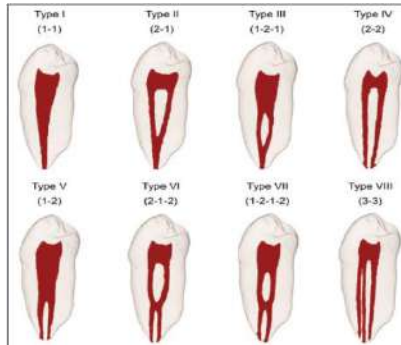
The number of root canal configurations were up to Type V based on Vertucci's classification. Moreover, in Indian population, very few case reports of mandibular canines with unusual root canal morphology were reported. CBCT technique has become a successful method to study the root canal anatomy and was reported to be as precise as root canal staining and clearing techniques which, in the past, was considered superior to conventional techniques and, that is, because its ability to produce a nondestructive 3D views and complete morphologic details.^[3,32] To the best of our knowledge, no study has so far evaluated the root canal morphology of mandibular canines in INDIAN subpopulation using CBCT.

Materials & Methods:-

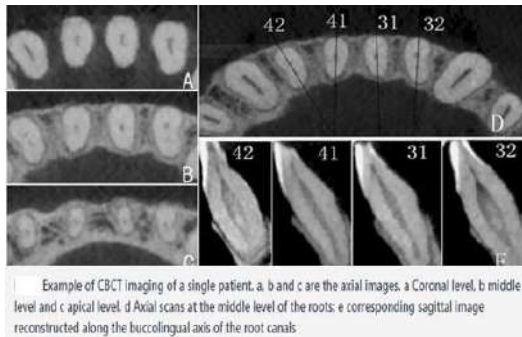
Fifty CBCT scans of patients (21 females and 28 males) aged between 15 and 60 years old were collected from a authorised CBCT center named 3D IMAGING CENTER located in AGRA. To ensure the reliability of the research results, two observer, a oral maxillofacial radiologist and a endodontist were present for analyses of variation in morphology to be seen in root canal of mandibular canines of 50 randomly selected CBCT images for accurate evaluation of numbers of canal present before start of any clinical procedure.

The presence of at least one mandibular right or left canine with fully developed roots was recorded in each image. Unclear or distorted CBCT images, previous endodontically initiated or treated teeth, presence of posts or crowns, periapical lesions, and any physiological or pathological process such as immature apex were excluded from the study. The total final sample

consisting of 50 mandibular canine teeth was evaluated in root canal configuration. The data were observed and recorded for canal configuration based on Vertucci's classification as shown in Figure 1.



The gender of the patients was also recorded. The CBCT images were evaluated by one endodontists and one oral maxillofacial radiologist, with a 3 years clinical experience, for root canal configuration in the axial, sagittal, and coronal planes. The images were collected from different CBCT machines: CS9300 3D digital imaging system (Carestream,) with a voxel size of 90–300µm with a voxel size . The exposure time was <15 s and the sample included CBCT images with either small or large field of view (FOV). The CBCT cross-sections were 10 mm thick viewed from the coronal to apical regions. The contrast and brightness of the images were adjusted to ensure optimal visualization with the software.



Out of total 50 teeth scans one tooth was excluded as it was seen that root malformed which implies that complete formation of one of tooth is not complete So, finally total 49 CBCT scans of permanent mandibular canine were 49 evaluated for variation in canal configuration (Cc) in which male was 28 and female was 21 as shown in table 2. Most of the teeth had one root (99.8%). Type I canal configuration (95.4%) was the most prevalent observation. The percentage of canal configuration in mandibular canine teeth are shown in table3.

Statistic Analysis :-

- The values are analyzed statistically using SPSS software version 21.0.
- Chi-square test, One Way Analysis of variance (ANOVA) test are performed to analyze the data obtained.
- P<0.05 are considered as statistically significant

Table Number of Teeth Evaluated :- 49

	Male	Female	Total
Canine	28	21	49

Configuration of the canals according to the Vertucci's classification found in 49 CBCT scans :-

Vertucci's classification	I	II	III	IV	V	VI	VII	VIII	Total number
Mandibular canine	41	7	1	0	0	0	0	0	49

Results :-

In result it was seen that CBCT images of patients(21 females and 28 males) were studied. The patient's CBCT scans were in the age ranged from 15 to 60 years. All of the examined teeth were single-rooted. In total 98 permanent mandibular canine were examined through CBCT scans. It was confirmed through CBCT scans which was evaluated according to Vertucci's configuration **Type 1(1)** canal configuration seen in 91 teeth that is around **84%** of permanent mandibular canine has a single canal which extends from pulp chamber to the apex . **Type II** canal configuration was found is **7(2-1)** teeth that is around **14%** of teeth have two separate canal which leaves the pulp chamber and join short of the apex to form one canal. **Type III(1-2-1)** canal was seen in only one teeth which come out be only **2%** . It means that only 2% of teeth have only one canal which leave the pulp chamber, divides into two within the root , and then merges to exist as one canal.

- Type I Canal configuration found in 91 teeth(84%),
- Type II Canal configuration found in 7 teeth(14%)
- Type III Canal configuration found in 1 teeth(2%).

Discussion:-

As early as 1870, the literature reveals periodic updates in the root canal morphology of teeth to learn more about their morphological variations, improve treatment techniques, and enhance treatment success rates. For this purpose, different methods have been used to study the root canal morphology.

CBCT are used for the assessment of root canal configurations. Panoramic evaluation of root canal configurations can be misleading because of its two-dimensional nature. The CBCT technique used in this study provides a 3D view of the root canal system. The variation in root canal morphology in the literature may be attributed to the difference in patient ethnicity even within the same population which is considered as a significant factor that may affect the perception of the clinician for the suspected root canal anatomy. CBCT technique provides diagnostic abilities which measured by determining the accuracy, specificity, and sensitivity of each finding. The voxel size, which is the smallest 3D data unit in CBCT, can determine the patient's exposure to radiation. Therefore, dental professionals should be aware and follow the basic principles of ("as low as reasonably achievable" principle). In general, the use of a restricted FOV has become the best choice for the endodontic diagnosis. 0.3-mm voxel size has been reported that it has greater accuracy in detection of the extra canal if present and lower radiation exposure.

Most mandibular canines in the present study had Type I canal configuration (84%), followed by Type II (14%), and Type III (2%). According to Vertucci's classification^[5] Type I was more frequent (78%) than the other canal configurations. These findings were similar to other studies where the prevalence of Type I was reported to be 81.5% in Mexican population, 80.39% in Turkish, 95.4% in Hamadani population in Iran, and 92% in South Asian Indian population.. Martins *et al.* reported that women had significantly more root canals than men in single rooted mandibular canine which coincides with the findings in our study. In contrary, Soleymani *et al* reported that mandibular canine with two canals were significantly more common among men than women.

Conclusion :-

In this study statistically analysis reveals presence of Type I canal configuration mostly seen in North Indian population with higher frequency in male scans of Cone beam computed tomography. So, by this study it is clearly shown CBCT scanning can be helpful for the mapping of root canal configurations which will help clinicians in complete debridement and obturation of all root canals and which can be achieved by detecting complex root canal configurations and clinicians should be aware of the root canal configurations before any endodontic procedure. If the complex root canal configurations are not detected and all of the root canals are not treated, they can result in the failure of root canal treatment

References

1. Vertucci FJ. Root canal morphology and its relationship to endodontic procedures. *Endod Topics* 2005;10:3-29.
2. Peikoff MD, Trott JR. An endodontic failure caused by an unusual anatomical anomaly. *J Endod* 1977;3:356-9.
3. Neelakantan P, Subbarao C, Subbarao CV. Comparative evaluation of modified canal staining and clearing technique, cone-beam computed tomography, peripheral quantitative computed tomography, spiral computed tomography, and plain and contrast medium-enhanced digital radiography in studying root canal morphology. *J Endod* 2010;36:1547-51.
4. Weine FS, Healey HJ, Gerstein H, Evanson L. Canal configuration in the mesiobuccal root of the maxillary first molar and its endodontic significance. *Oral Surg Oral Med Oral Pathol* 1969;28:419-25.
5. Vertucci FJ. Root canal anatomy of the human permanent teeth. *Oral Surg Oral Med Oral Pathol* 1984;58:589-99.
6. Gulabivala K, Aung TH, Alavi A, Ng YL. Root and canal morphology of burmese mandibular molars. *Int Endod J* 2001;34:359-70.
7. Pineda F, Kuttler Y. Mesiodistal and buccolingual roentgenographic investigation of 7,275 root canals. *Oral Surg Oral Med Oral Pathol* 1972;33:101-10.
8. Ouellet R. Mandibular permanent cuspids with two roots. *J Can Dent Assoc* 1995;61:159-61.
9. Cleghorn BM, Christie WH, Dong CC. Anomalous mandibular premolars: A mandibular first premolar with three roots and a mandibular second premolar with a C-shaped canal system. *Int Endod J* 2008;41:1005-14.
10. Somalinga Amardeep N, Raghu S, Natanasabapathy V. Root canal morphology of permanent maxillary and mandibular canines in Indian population using cone beam computed tomography. *Anat Res Int* 2014;2014:731859.
11. Zhengyan Yang, Lu Keke Wang Fei Li Yueheng Zhou Zhi, Cone-beam computed tomography study of the root and root canal morphology of mandibular permanent anterior teeth in a Chongqing population. *Ther Clin Risk Manag* 2015 Dec 23;12:19-25.
12. Verma GR, Bhadage C, Bhoosreddy AR, Vedpathak PR, Mehrotra GP, Nerkar AC, Bhandari A, Chaubey S. CBCT Study of Root Canal Morphology of Permanent Mandibular Incisors in Indian Subpopulation. *Pol J Radiol.* 2017 Jul 7;82:371-375.

13. Aminsobhani M, Sadegh M, Meraji N, Razmi H, Kharazifard Evaluation of the root and canal morphology of mandibular permanent anterior teeth in an Iranian population by CBCT. *MJJ Dent (Tehran)*. 2013 May;10(4):358
14. Shemesh A, Kavalarchik E, Levin A, Ben Itzhak J, Levinson O, Lvovsky A, Solomonov M. Root Canal Morphology Evaluation of Central and Lateral Mandibular Incisors Using Cone-beam Computed Tomography in an Israeli Population. *J Endod*. 2018 Jan;44(1):51-55
15. Rahimi S, Milani AS, Shahi S, Sergiz Y, Nezafati S, Lotfi M. Prevalence of two root canals in human mandibular anterior teeth in an Iranian population. *Indian J Dent Res*. 2013 Mar-Apr;24(2):234-6 .
16. Altunsoy M, Ok E, Nur BG, Aglarci OS, Gungor E, Colak M. A cone-beam computed tomography study of the root canal morphology of anterior teeth in a Turkish population. *Eur J Dent*. 2014 Jul;8(3):302-6.
17. Boruah LC, Bhuyan AC. Morphologic characteristics of root canal of mandibular incisors in North-East Indian population: An in vitro study. *J Conserv Dent*. 2011 Oct;14(4):346-50.