

## BORN WITH TEETH, NORMAL/ABNORMAL- A CASE REPORT

Kriti Mainali <sup>1</sup>, Jasheena Singh <sup>2</sup>, Nidhi Gupta <sup>3</sup>, Sashank Soni <sup>4</sup>

Post Graduate Student <sup>1,4</sup>, Prof & Head <sup>2</sup>, Professor <sup>3</sup>

1-3- Department of Pedodontics and Preventive Dentistry, M.P.C.D. & R.C., Gwalior, Madhya Pradesh, India

4- Department of Orthodontics and Dentofacial Orthopaedics, M.P.C.D. & R.C., Gwalior, Madhya Pradesh, India

### Abstract

Natal teeth and neonatal teeth are the rare developmental anomaly affecting new-borns with a prevalence ranging from 1:716 to 1:30,000. The major reasons of parents seeking for dental care are difficulty during suckling/feeding, minor injury to the mother's breasts, sublingual ulceration (Riga fede disease) and aspiration of the teeth. The case report presents a 3-day-old girl child with natal teeth and its treatment opted.

**Key Words:** Epinephrine, Extraction, Mucosal Swelling, Natal teeth

### INTRODUCTION

Early erupted primary teeth present at birth have been termed as 'congenital teeth', 'foetal teeth' or 'dentition praecox. Massler and Savara <sup>2</sup> termed 'natal teeth' for teeth present at birth in 1950. King and Lee <sup>1</sup> reported the incidence more seen with lower primary central incisors with usual occurrence in pairs. The hypothesis for the most common etiology includes trauma, hypovitaminosis, hormonal stimulation, febrile states and syphilis. However, in the current theory, the presence of natal/neonatal teeth is the early eruption of superficially positioned developing tooth germ. Histological examinations shows that most of the crowns have hypoplastic enamel which may have variable degrees of severity, lack of root formation, uneven dentin formation, and deficient cementum formation. In 1997 Hebling classified natal teeth into following categories:

Category 1: A shell-like crown structure loosely attached to the alveolus by a rim of oral mucosa, no root.

Category 2: A solid crown loosely attached to the alveolus by oral mucosa, little or no root. Category 3: The incisal edge of the crown just erupted through the oral mucosa.

Category 4: A mucosal swelling with the tooth unerupted but palpable.

### CASE REPORT

A baby girl of 3 days old reported to the Department of Pedodontics and Preventive Dentistry (Maharana Pratap College of Dentistry and Research Centre, Gwalior) with the chief complain of presence of teeth in lower front teeth region noticed since birth. The primary concern was the anticipation of her feeding and negative cultural attitudes. The child was clinically evaluated and her discharge history carefully valued. The child had one erupted natal tooth (clinically visible) whereas the other one was covered by the gingival (palpable). The overlying gingiva was red, swollen and natal teeth had grade III mobility. Intramuscular Vitamin K administration was confirmed with the paediatrician and the treatment option of extraction was decided.

After explaining the situation and obtaining verbal consent, extraction was done under topical anaesthesia

with epinephrine. Post extraction haemostasis was achieved. Postoperative instructions were given and a recalled after a week for further evaluation.

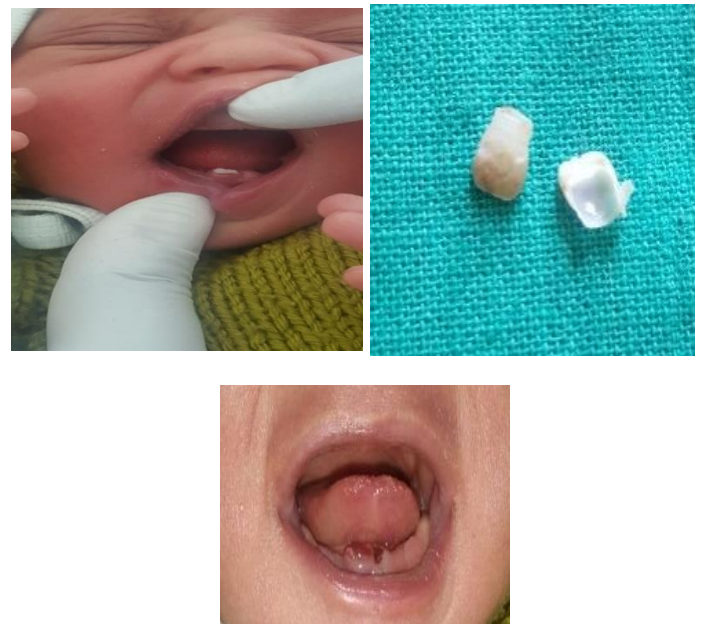


Figure A: Pre- Operative, Figure B: Extracted natal teeth, Figure C: Post-Operative)

### DISCUSSION

The form of these teeth depends upon the degree of maturity where the most common appearance is unattached, small, stained, and hypoplastic tooth. The majority of which may exhibit a brown-yellowish or whitish-opaque colour.<sup>6</sup>

Other oral signs that may confuse the clinician are cysts of the dental lamina and Bohn nodules, for which radiographic examination can be done to differentiate.

Smoothing of the incisal margin was the option reported by Martins<sup>7</sup> to prevent lacerations to the child's own tongue and also to the mother's nipples. Goho<sup>8</sup> also reported that incisal portion of the tooth could be covered with composite resin for the similar reasons.

The choice of preserving these teeth or not depends on factors like degree of movement, problems during

Suckling/feeding, possibility of trauma to the child or mother, and whether the tooth is part of the normal dentition or not<sup>4</sup>. Many a time's parents also opt for extraction of the teeth because of social taboos.

Teeth that have been stable for four months and more have a decent prognosis. Although many investigators have talked about the risk of aspiration of these teeth, in reality, there are no reports in the literature to support. Still, cases of spontaneous tooth exfoliation have also been reported. Therefore the conclusion could be drawn that the early erupted teeth has to be carefully inspected for further need of treatment.

#### REFERENCES

1. Zhu J, King D. Natal e neonatal teeth. *J Dent Child* 62:123- 128, 1995.
2. Massler M, Savara BS. Natal and neonatal teeth: a review of 24 cases reported in the literature. *J Pediatr* 36:349-359, 1950.
3. Hebling J, Zuanon ACC, Vianna DR. Dente Natal— A case of natal teeth. *Odontol Clín* 7:37-40, 1997
4. <http://www.newdao.com/natal-teeth-baby-born.html> .
5. Khandelwal V, Nayak UA, Nayak PA, et al. *BMJ Case Rep* Published online:doi:10.1136/ bcr-2013-010049.
6. F. A. Gonçalves, “Natal teeth: review of the literature and report of an unusual case,” *Brazilian Dental Journal*, vol. 9, no. 1, pp. 53–55, 1998.
7. Martins ALCF. Erupção dentária: dentes decíduos e sintomatologia desse processo. In: Corrêa MSNP, editor. , ed. *Odontopediatria na Primeira Infância*. São Paulo: Santos, 1998:117–29
8. Goho C. Neonatal sublingual traumatic ulceration (Riga-Fede disease): reports of cases. *J Dent Child*1996;2013:362–4
9. Howkins C. Congenital teeth. *Br Dent Assoc* 53:402-405, 1932.
10. Ooshima T, Mihara J, Saito T, Sobue S. Eruption of toothlike structure following the exfoliation of natal tooth: report of case. *J Dent Child* 53:275-278,1986
11. Rusmah M. Natal and neonatal teeth: a clinical and histological study. *J Clin Pediatr Dent*1991;2013:251–3

#### Corresponding Author

Dr. Shashank Soni  
Post Graduate Student  
Department of Orthodontics  
M.P.C.D. & R.C., Gwalior , Madhya Pradesh, India  
Email-shashanksoni@gmail.com

**How to cite this article:** Mainali K, Singh J, Nidhi G, Soni S, Born with Teeth, Normal/Abnormal- A Case Report, *TMU J Dent* 2018;5:27-31.